

Segmentation and detection of lung cancer in CT image using active contour method

Nciri Walid ^{*1}, Benzarti Faouzi ^{*2}

**University of Tunis El Manar, National Engineering School of Tunis
LR-SITI Laboratory Signal, Images and Technology of Information, 1002, Tunis, Tunisia*

¹walid-nciri-40@hotmail.com

²benzartif@yahoo.fr

Abstract— Lung cancer continues to be the most diagnosed cancer type and the principal cause of cancer deaths worldwide. To increase the chance of survival, segmentation is an essential step in the diagnosis of cancer. Therefore, this paper represents an algorithm of segmentation and detection of lung cancer through a method very useful in image processing because of their effectiveness which is the active contour method. The proposed methodology focuses on acquisition of CT images, pre-processing when RGB image is converted into gray scale image and then the noise is removed from this image using median filter. The use of morphological operations is after the lungs segmentation from the original CT image using active contour. The main aim of this process was to remove the portions that are part of the CT image other than lung lesion. The proposed system is implemented in MATLAB software.

Keywords— Lung cancer, Pre-processing, Segmentation, Active contour, Nodule detection

I. INTRODUCTION

Lung cancer continues to be the most diagnosed cancer type and the leading cause of for cancer related deaths worldwide. According to the American Cancer Society, the five-year survival rate is not more than %15. To increase the chance of survival, early detection of suspicious lesions is vastly important [11].

The tumors that appear in the lung can be: micro-nodules if they are less than 7 mm in diameter, nodules if their size is between 7 and 30 mm in diameter, masses if they are more than 3 cm, in this paper we are interested in the 3rd type of nodule (mass) that usually presents really lung cancer.

The radiography of lungs (or pulmonary radiography) is an examination which allows to get images of the inside of lungs with the aid of an machine with X-rays. Pulmonary radiography does not always make it possible to detect a nodule, even if it is actually present in the lung.

For detecting pulmonary nodules, computed tomography (CT) is superior to radiography, and it is now being used in many studies for the early detection and analysis of lung nodules [12]. CT scans are widely used for short-term follow up to identify nodules volumetric changes over time. The change of the volume can be used as an indicator of malignancy. Meanwhile, automatic measurements of nodule

volumes has been increasingly used as a reproducible (higher intra-observer agreement) and accurate technique [13].

In the literature, Many of the nodule segmentation methods are present. Among various segmentation methods, active contour was one of the most popular and successful one. Many researchers are devoted to study the detection of pulmonary nodules attached to vessels and the pulmonary wall. Kuhnigk et al. proposed a method for segmenting both small and large lesions [1]. They have used fixed thresholding and introduced morphological opening in order to remove vascularity connected to lesions. Their method is less effective on sub-solid nodules. Moltz et al. extended this work to deal with challenges such as segmenting nodules that are attached to non-convex parts of the pleura [2]. They proposed a ray-casting-based ellipsoid approximation for enclosing juxta-pleural lung nodules followed by a convex hull operation. This algorithm was focused on solid nodules. Dehmeshki et al. operated region growing algorithm within a predefined volumetric mask which indicates foreground and background regions [3]. Their results were visually inspected by a radiologist and 84% of the segmentation results were accepted. The unaccepted nodules were mostly very close to lung wall, diaphragm or they were vascularized. Kubota et al. proposed a method to segment various density types [4]. Their algorithm first located the core of the nodule and afterwards detached the nodule from attached structures by a region growing algorithm. Finally, it applied a convex hull processing. Tao et al. proposed a multi-level learning-based framework that integrates detection and segmentation of ground glass nodules on improving accuracy [2]. They demonstrated their method on an 1100 nodule dataset. Finally, Messay et al. proposed a new algorithm which had three options on segmenting pulmonary nodules. These included a fully-automated, a semi-automated and a hybrid system. The automatic system required a user defined cue point and also has 2 free parameters. These free parameters are determined for each nodule in a search process guided by a regression neural network. This system is successful in segmenting pulmonary nodules but needs high computational power. Furthermore, it removes vessels using morphological operations and results were not given for sub-solid and nonsolid nodules [5]. El-Bazl et al. [6] proposed a segmentation technique using Markov random field, consisting of two stages. The first stage is to select the

optimum decision level to create an initial labeling image, and the second one is to extract the lung tissues from each slice. Tong et al. [7] used a three step process to detect lung nodules. Firstly, an adaptive threshold algorithm was used to segment the lung region. Secondly, active contour model (ACM) was used to remove lung vessel and finally a Hessian matrix (selective shape filter) was used to detect the suspicious nodules. This method was able to produce an overall detection rate of 85%. Marten et al. [8] evaluated and compared features such as nodule size, position, margin, matrix characteristics, vascular and pleural attachments with gold standard. Azimifar et al. [9] used active contour modeling for segmentation and produces an overall detection rate of 89%. Dehmeshki et al. [10] proposed volumetric measurement for the detection of lung nodule.

The organization of this paper is as follows: this section reviews the research related works of lung segmentation. The detailed proposed method for segmentation and detection of nodule using active contour model are presented in Section 2. Section 3 presents the experimental results. Finally, the conclusion and directions for future work are given in Section 4.

II. PROPOSED METHOD

Here, a system for lung segmentation and nodule detection is proposed from CT scan images. The following figure shows the block diagram of the proposed system.

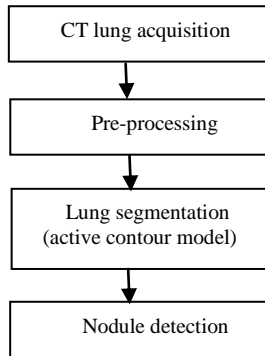


Fig. 1 Block diagram of the proposed system

A. Image acquisition

Here, the input images are chest CT scan images in JPEG format that contain tumors. The user has to select the required lung CT scan image for further processing. The images were acquired by the system and saved in a personal computer.

B. Pre-processing

Pre-processing includes following steps:

1) *Median filter*: The median filter is also the simpler technique and it removes the speckle noise from an image and also removes pulse or spike noise [14-15]. The Median Filter is performed by taking the magnitude of all of the vectors within a mask and sorting the magnitudes. The pixel with the

median magnitude is then used to replace the pixel studied. The operation of median filter can be expressed as:

$$f(x,y) = \text{median}_{(s,t) \in S_{xy}} \{g(s,t)\} \quad (1)$$

where S_{xy} represents the set of coordinates in a rectangular sub image window, centered at point (x,y) , and median represents the median value of the window.

2) *Morphologic operation*: A binary image can be viewed as a binary valued function of x and y . Morphological theory views a binary image as the set of its foreground (1-valued) pixels, the elements of which are in Z^2 . Set operations can be applied directly to binary image sets. The operations of dilation and erosion are fundamental to morphological image processing [16,17].

Dilation is an operation that “grows” or “thickens” objects in a binary image. The specific manner and extent of this thickening is controlled by a shape referred to as a structuring element. Mathematically, dilation is defined in terms of set operation. The dilation of A by B , denoted $A \oplus B$.

$$A \oplus B = \left\{ z \mid (\hat{B})_z \cap A \neq \emptyset \right\} \quad (2)$$

Where \emptyset is the empty set, B is the structuring element. \hat{B} is the reflection of set B , is defined as

$$\hat{B} = \{w \mid w = -b, b \in B\} \quad (3)$$

The translation of set X by point $z = (z_1, z_2)$ denoted $(X)_z$, is defined as

$$(X)_z = \{c \mid c = a + z, a \in X\} \quad (4)$$

The dilation of A by B is the set consisting of all the structuring element origin locations where the reflected and translated B overlaps at least some portion of A .

Erosion “shrinks” or “thins” objects in a binary images. The manner and extent of shrinking is controlled by a structuring element. Mathematically, erosion is defined in terms of set operation. The erosion of A by B , denoted $A \otimes B$, is defined as

$$A \otimes B = \left\{ z \mid (B)_z \cap A^c \neq \emptyset \right\} \quad (5)$$

Where \emptyset is the empty set, B is the structuring element. The set of all pixel coordinates that do not belong to set A , denoted A^c , is given by

$$A^c = \{w \mid w \notin A\} \quad (6)$$

The erosion of A by B is the set of all the structuring element origin locations where the translated B has no overlap with the background of A .

C. Post processing:

Post-processing includes following steps:

1) *Lung segmentation:* In this module we segment left and right lung from the CT image. The active contour models (ACM) [18], which are based on the theory of surface evolution and geometric flows, have been extensively studied and successfully used in image processing generally and in this paper specifically. To simplify the work we used a MATLAB (R2014) function which is as follows:

$$bw = \text{activecontour}(A, \text{mask}, n) \quad (7)$$

This function is used to segments the 2-D grayscale image A into foreground (object) and background regions using active contour based segmentation. The output image bw is a binary image where the foreground is white (logical true) and the background is black (logical false). mask is a binary image that specifies the initial state of the active contour. The boundaries of the object region(s) (white) in mask define the initial contour position used for contour evolution to segment the image. To obtain faster and more accurate segmentation results, specify an initial contour position that is close to the desired object boundaries, n is the number of iterations.

2) *Nodule detection:* The reconstruction of the lung border is an important step that aims to recover lung nodules that are attached to the thoracic wall [19]. The MATLAB function is used in this work to isolate these pulmonary nodules and then to diagnose it later.

III. RESULTS OF EXPERIMENTATION

A. Results

In this section, the results of the proposed system are shown for five images from the database.

It has been observed that the CT image of the lung is composed of a chest wall and an outer part, although just the chest wall is interesting then in our system we have to crop the image at the beginning as illustrated in Fig. 2.

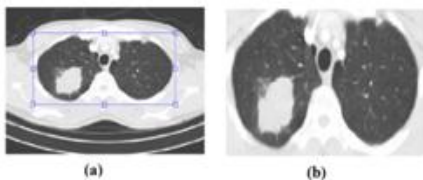


Fig. 2 Example of crop image, (a) Original image, (b) image after crop.

The original image, the image after segmentation through the active contour approach and output for different candidates are shown in Table 1.

B. Discussion

Manual segmentation of pulmonary nodules is not feasible in clinical practice since it takes approximately 10 minutes for an expert radiologist to trace a nodule. In order to overcome this issue, scientists are trying to create automated accurate,

robust and reproducible systems. So far, a system that fulfills all these features is not present [19]. We have presented a fully-automated, computationally efficient method for segmenting the pulmonary nodule, based on active contour model. The method has been validated quantitatively on a database of lung cancer patients. For oblique fissures, the mean distances are typically <3mm. The evaluation of our system is done through the following parameters which are calculated on the basis of the results obtained for all images in the database :

- TP: True lung separation and true nodule detection.
- TN: True lung separation and false nodule detection.
- FP: False lung separation and true nodule detection.
- FN: False lung separation and true nodule detection.

1) Accuracy:

$$(AC) = \frac{TP + TN}{TP + TN + FP + FN} = 0.8461 \quad (7)$$

Accuracy in % = 84.61 %

2) Sensitivity

$$(SE) = \frac{TP}{TP + FN} = 0.8333 \quad (8)$$

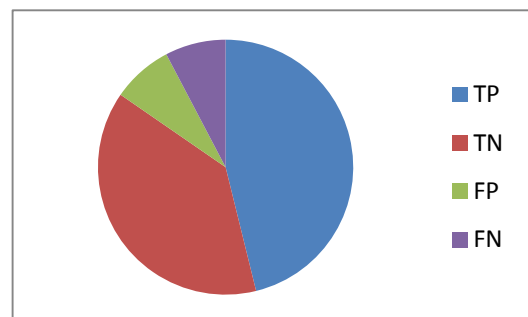
Sensitivity in % = 83.33 %

3) Specificity

$$(SP) = \frac{TN}{TN + FP} = 0.8571 \quad (9)$$

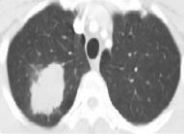



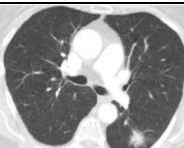








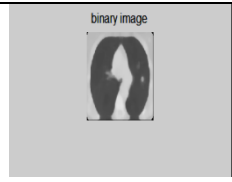


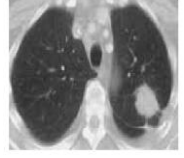
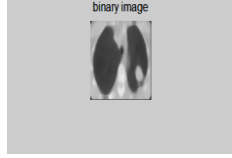


Specificity in % = 85.71 %

Thus, from the results we found that our proposed system has achieved 84.61 % accuracy, specificity of 83.33 % and good sensitivity i.e. 85.71 %.



Graph. 1 Accuracy parameters

TABLE 1. RESULT OF DIFFERENT SUBJECT

(a) Input image	(b) Filtered image	(c) Segmented lungs	(d) Nodule detection
			
			
			
			
			

IV. CONCLUSION

In this paper, a detailed description has been made of the different stages of our segmentation system. This segmentation is based on active contour model. The nodule or cancer detection step is carried out using MATLAB is successfully done with 84.61% accuracy.

As a working perspective, it would be interesting to use 3D models can be to improve the performance of pulmonary nodule segmentation, furthermore it would also be interesting to work on the small nodule that are less than 3mm.

REFERENCES

[1] J. M. Kuhnigk, V. Dicken, L. Bornemann, A. Bakai, D. Wormanns, S. Krass, and H. O. Peitgen, "Morphological Segmentation and Partial Volume Analysis for Volumetry of Solid Pulmonary Lesions in Thoracic CT Scans," *IEEE T Med Imaging*, vol. 25, no. 4, pp. 417- 434, April 2006.

[2] J. H. Moltz et al. "Advanced Segmentation Techniques for Lung Nodules, Liver Metastases, and Enlarged Lymph Nodes in CT Scans," *IEEE J Sel T Sign Proc*, vol. 3, no. 1, pp. 122-134 , February 2009.

[3] J. Dehmeshki, H. Amin, M. Valdiviesco, and X. Ye, "Segmentation of Pulmonary Nodules in Thoracic CT Scans: A Region Growing Approach," *IEEE T Med Imaging*, vol. 27, no. 4, pp. 467-480, April 2008.

[4] T. Kubota, A. K. Jerebko, M. Dewan, M. Salganicoff, and A. Krishnan, "Segmentation of pulmonary nodules of various densities with morphological approaches and convexity models," *Medical Image Analysis*, vol. 15, no. 1, pp. 133-154, 2010.

[5] T. Messay, R. C. Hardie, and T. R. Tuinstra, "Segmentation of pulmonary nodules in computed tomography using a Regression neural network approach and its application to the Lung Image Database Consortium and Image Database Resource Initiative Dataset," *Medical Image Analysis*, vol. 22, pp. 48-62, February 2015.

[6] Ayman El-Bazl, Aly A. Farag, Robert Falk, Renato La Rocca, Automatic identification of lung abnormalities in chest spiral CT scans, *ICASSP (2003)* 261–264.

[7] Jia Tong, Wei Yin, Wu Cheng Dong, A Lung cancer lesions detection scheme based on CT image, *Int. Conf. Signal Process. Syst. (2010)* 557–560.

[8] K. Martena, C. Engelke, T. Seyfarth, A. Grillho" sl, S. Obenauer, E.J. Rummeny, Computer-aided detection of pulmonary nodules: influence of nodule characteristics on detection performance, *Clin. Radiol. 60 (2005)* 196–206.

- [9] Zohreh Azimifar, Mohsen Keshani, Farshad Tajeripour, Reza Boostani, Lung nodule segmentation and recognition using SVM classifier and active contour modeling: a complete intelligent system, *Comput. Biol. Med.* 43 (2013) 287–300.
- [10] Jamshid Dehmeshki, Hamdan Amin, ManlioValdivieso, Xujiong Ye, Segmentation of pulmonary nodules in thoracic CT scans: a region growing approach, *IEEE Trans. Med. Imaging* 27 (4) (2008) 467–480.
- [11] American Cancer Society (2012). Cancer fact and figures [Online]. Available: <http://www.cancer.org/research/cancerfactsfigures/cancerfactsfigures/cancer-facts-figures-2012>
- [12] S. Diciotti, G. Picozzi, M. Falchini, M. Mascalchi, N. Villari, and G. Valli, "3-D Segmentation Algorithm of Small Lung Nodules in Spiral CT Images," *IEEE T Inf Technol B*, vol. 12, no. 1, pp. 7-19, January 2008.
- [13] J. Dehmeshki, H. Amin, M. Valdiviesco, and X. Ye, "Segmentation of Pulmonary Nodules in Thoracic CT Scans: A Region Growing Approach," *IEEE T Med Imaging*, vol. 27, no. 4, pp. 467-480, April 2008.
- [14] R. C. Gonzalez and R. E. Woods, *Digital Image Processing, Third Edition* (Prentice-Hall, 2007) ISBN-10:013168728.
- [15] T. Acharya and A. K. Ray, *Image Processing Principles and Applications* (John Wiley & Sons Canada, Ltd. 2005) ISBN: 0471719986.
- [16] Rafael C. Gonzalez, Richard E. Woods, Steven L. Eddins, "Digital Image Processing", Publishing House of Electronics Industry, Beijing,2005
- [17] Haibo Wang, Jing Zhang, Jianzhi Wang, "The Auto-segmentation Algorithm for Pulmonary Parenchyma of CT Image Based on Linear Filtration", *IEEE*, 2010.
- [18] Kaihua Zhang, Huihui Song, Lei Zhang, " Active contours driven by local image fitting energy", *Pattern Recognition journal*, vol. 43, pp.1199-1209, April 2010.
- [19] Ezhil E. Nithila , S.S. Kumar, "Segmentation of lung nodule in CT data using active contour model and Fuzzy C-mean clustering", *Alexandria Engineering Journal*, pp. 2583–2588, 2016.