

Quantitative T2 relaxation time analysis of Achilles tendon in vivo at 3Tesla

TBINI Zeineb¹, MARS Mokhtar¹, BOUAZIZ CHELLI Mouna²

Laboratory of Research in Biophysics and Medical Technologies, El Manar University, Higher Institute of Medical Technologies of Tunis, 09, Rue Doctor Zouheir Safi -1006 Tunis, Tunisia¹

zeinebtbini@gmail.com mokhtar.mars-mms@topnet.tn

Faculty of Medicine of Tunisia, Radiology Department, Mohamed Kassab Institute of Orthopedics, 2010 Ksar Saïd, Tunisia²

bouaziz_mouna@yahoo.fr

Abstract To quantify T2 relaxation time in Achilles tendon and to evaluate regional variations of T2 in healthy volunteers and patients with chronic tendinopathy. Seventeen asymptomatic volunteers and sixteen symptomatic patients were examined for ankle at 3T MRI system using head coil. T2 mapping was acquired using Multi Echo Spin Echo sequence (MESE) in sagittal plane. T2 was calculated using a self-developed matlab mono-exponential analysis algorithm in three regions (insertion tendon, mid portion and musculotendinous junction) of Achilles tendon. Differences between T2 values were considered significant if $p < 0.005$. Means values of T2 for controls tendons and pathologic tendons were 13.24 ± 2.76 ms and 24.75 ± 3.61 ms respectively. There was a significant difference between the three regions in patients and volunteers $p = 0.001$ ($p < 0.05$). T2 mapping is a robust tool to characterize Achilles tendinopathy and regional variability of Achilles tendon can be quantified by T2 relaxation time.

Key words Achilles tendon, Tendinopathy, MRI, T2 mapping, mono-exponential fitting.

I. INTRODUCTION

Achilles tendon (AT) is a fibrous connective tissue that connects the triceps surae muscle to the calcaneus bone. It is the biggest and most powerful tendon of the human body.^[1] Its main role is the transmission of the muscle strength and therefore generates movement. Indeed, it supports the most important loads of body, especially during physical activities.^[2, 3] It can support loads more than 3500 N during an activity.^[3] However, in the last decades, Achilles tendon injuries have increased, they are common in athletes and general public.^[4] Achilles tendon pathology are mostly divided into inflammatory enthesitis which refers to inflammation of the entheses and tendinopathy which refers to mechanical, biochemical, degenerative and overuse disease.^[4, 5] Generally, tendinopathy is the common cause of Achilles tendon pain. It is associated with histopathological changes such as hyper vascularity, focal variation in cellularity, degeneration of collagen fibers, and disorganization of the classic hierarchic structure as well as increased in mucoid, proteoglycan and water content.^[5, 6, 7]

Tendinopathy treatments are multiple depends on clinical forms and etiology, but the efficiency of these treatments depends on the accuracy of the diagnosis and the stage of the pathology, therefore a noninvasive early assessment of Achilles tendon disorders may enhance the diagnosis and the characterization of recovery treatments.

Currently, there is different imaging modalities used in the diagnostic assessment of Achilles tendinopathy. The most commonly used are ultrasound and magnetic resonance imaging (MRI). Each modality has a critical impact in the diagnostic evaluation and assessment of patients with problems at and around the Achilles tendon.^[8]

^{9]} Ultrasound has been widely used, it provides a non-invasive tool of assessing the tendon's response to therapy and progression of disease, but it is user-dependent and it's limited in some pathologic condition.^[10] MRI is a powerful non-invasive diagnostic tool when the diagnosis is uncertain. It has been used as an accurate qualitative and quantitative diagnostic tool which provides excellent soft-tissue contrast and the possibility to reconstruct in three dimensions. Also it can provide information about the pathologic state of Achilles tendon, morphology and tear size.^[11]

In conventional T1, T2 and proton density weighted MRI sequences, the signal intensity contrast between tissues can differentiate between normal and symptomatic Achilles tendon but it is less reliable in the diagnostic of chronic injuries associated with histological and biochemical disorders which happens in early stage. In addition to morphological imaging, quantitative parametric MRI has been developed to assess biochemical properties of tissues and quantify the differences between symptomatic and asymptomatic tissues.^[11]

^[12] At the first, this technique has been employed to quantify biochemical changes in cartilage.^[13, 14, 15] It has been demonstrated a good sensitivity in the detection of earlier biochemical changes in various tissues.^[12, 16, 17, 18] Before morphological changes, the Achilles tendon is subjected to biochemical alterations. Biochemical changes in the Achilles tendon are related to proteoglycan loss and

disorganization of the collagen matrix, which becomes less elastic allowing increased mobility of water and consequentially increased levels of H₂O proton content which leads to an increased T2 relaxation values compared to normal levels. [16, 17, 18]

Recently, several quantitative parametric MRI techniques are under development. T2 mapping is one of such technique which is the most widely available for clinical use because it is readily available on most scanning platforms. [12, 14, 16] T2 mapping is more sensitive to the changes of the collagen fibers structure, orientation and water content. It's able to quantify changes in collagen matrix integrity and water content. Also, it can monitor the levels of injuries to improve MRI diagnosis for treatment planning. [19, 20, 21, 22] The aim of this study is to assess T2 values in Achilles tendon using intermediate TE imaging at 3T in vivo, to evaluate the efficiency of T2 mapping in detecting Achilles tendon disease among patients with tendinopathy compared to asymptomatic volunteers and to evaluate the regional variation of T2 values in healthy and tendinopathic Achilles tendon.

II. MATERIALS AND METHODS

Our study was approved by the local Ethics Committee and written informed consent was obtained from each subject.

A. Population

Seventeen asymptomatic volunteers without clinically evident of Achilles tendinopathy (7 males and 10 females, mean age 40,47±18 years, BMI 23,64±8.02kg/m²) were included in the study. Exclusion criteria's include a history of Achilles tears or major trauma to the ankle.

Sixteen symptomatic patients with different stages of Achilles tendinopathy (6 males and 10 females, mean age 52±15years, BMI 28.68±6.15kg/m²) were examined. Inclusion criteria's were chronic or acute tendinopathy, tendinosis of the mid-portion of the Achilles tendon, tendinitis and traumatic or degenerative enthesopathy. Exclusion criteria's were traumatic Achilles pathology and peritendinitis.

B. Clinical examination

A clinical exam and questionnaire analysis were realized for all subjects and an ultrasound dynamic examination of ankle was realized for all symptomatic patients by an expert in musculoskeletal sonography (23 years of experience). Ultrasound was performed in longitudinal and transverse orientation to assess and identify the Achilles pathology.

C. MRI Examination

Ankle images were acquired using a 3 Tesla scanner (Magnetom Verio, Siemens Erlangen,

Germany) equipped with a 12 channel head coil. All subjects were positioned in the isocenter of the magnet, feet-first, supine position and both feet in flexion position but only one foot was placed in the coil. Patients were asked to stop all hard physical activities during 24 hours before the MR examination; also they were stayed on rest a period of 15 minutes before MR imaging.

The morphological imaging protocol of the Achilles tendon included a turbo spin echo FAT-SAT sequences weighted protons density (TSE FS PD) in sagittal and axial planes. The details of scanning parameters are listed in Table I. For quantitative T2 assessment a Multi Echo Spin Echo (MESE) sequence in the sagittal plane was used. Scanning parameters were as follow: repetition time 1500ms, echo time 8.1, 16.2, 24.3, 32.4 and 40.5 ms, field of view 280*280, matrix 205*256, slice thickness 3mm, bandwidth 250 Hz/pixel, flip angle 180° and acquisition time 2.5 min.

TABLE I

Scanning parameters for the sequences used for morphological assessment of the Achilles tendon.

Sequences Parameters	TSE PD sagittal	TSE PD axial
Repetition time (ms)	3000	3430
Echo time (ms)	36	36
Field of view (mm*mm)	240*240	163*180
Bandwidth (Hz /pixel)	237	237
Matrix	384*384	244*384
Dimension	2D	2D
Slice thickness (mm)	3	4
Acquisition time (min)	2:27	3:57

D. Image analysis and T2 calculation

Morphological evaluation of ankle and Achilles tendon was performed on sagittal and axial images acquired using TSE FS PD by a radiologist expert in musculoskeletal MRI (23 years of experience) to confirm the inclusion and exclusion criteria's in all patients.

T2 values were measured using a least squares fitting algorithm written in MATLAB (MATLAB2009a). The analysis algorithm was executed offline on sagittal images obtained with our quantitative scanning protocol. Three region of interest (ROI's) were manually drawn in the Achilles tendon (insertion tendon (INS), mid portion (MID) and musculotendinous junction (MTJ)) and a mono-exponential curve was used to determine T2 relaxation times. The length of each region was defined as a third of the total Achilles tendon length, measured from the most proximal to the most distal. [23] See figure 1.

Our Mono-exponential curve fitting algorithm was performed as follow. First, we choose a series of five images with variable echo time and the same slice position. Then, we draw the ROI in the Achilles tendon in one image, and propagate it to

all images. The mean intensities of pixel in each ROI's were used to plot the transverse relaxation T2 curve:

$$S=f(TE) \quad \text{Eq.1}$$

With S the mean value in ROI and TE is the echo time. In theory, S refers to the transverse magnetization M_{xy} .

$$M_{xy}(TE)=M_0 \cdot \exp(-TE/T_2) \quad \text{Eq. 2}$$

T2 value was derived through the mono-exponential fitting of the equation:

$$Y=A \cdot \exp(-t/B) \quad \text{Eq.3}$$

Where A refers to the signal intensity at $TE=0$ ms, B refers to T_2 .

T2 maps were calculated by the same adjustment procedure performed on a pixel-by-pixel basis.

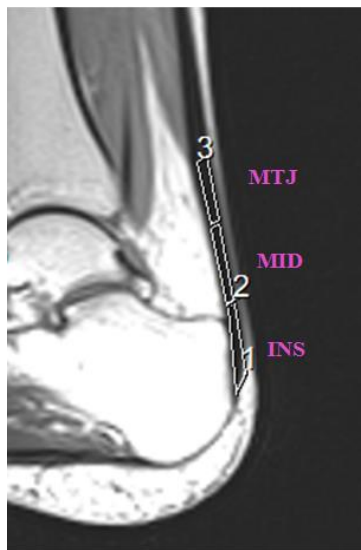


Fig. 1 Different ROI's on Achilles tendon of 27-year-old healthy volunteer, $TE = 8.1$ ms.

E. Statistical analysis

Statistical analysis was performed with SPSS version 15 software. First, means and standard deviation (SD) of age and BMI for both groups were calculated. Second, means and standard deviation (SD) of T2 in each region were calculated for patients and volunteers. And, a paired sample T-test was realized to compare mean T2 values of different anatomical regions between the two groups. The level of significance was set to $P < 0.05$.

III. RESULTS

Volunteers group were classified as asymptomatic for ankle pathology based on questionnaire analysis and clinical exam. However, one of the seventeen volunteers was excluded due to an evident trauma of the ankle found during the morphologic MRI evaluation.

Two patients among the sixteen were excluded due to an old tear of Achilles tendon found during the ultrasound exam and morphological evaluation. The means values of T2 relaxation time for the controls tendons and tendinopathic tendons were 13.24 ± 2.76 ms and 24.75 ± 3.61 ms respectively. An

example of mono-exponential fit of data for a volunteers (age 27-year-old and $BMI=21$ kg/m²) is shown in figure 2. There was a significant difference in T2 relaxation time between the symptomatic and the asymptomatic tendons $p = 0.01$ ($p < 0.05$). Examples of T2 maps from a volunteer and a patient are depicted in figures 3 and 4.

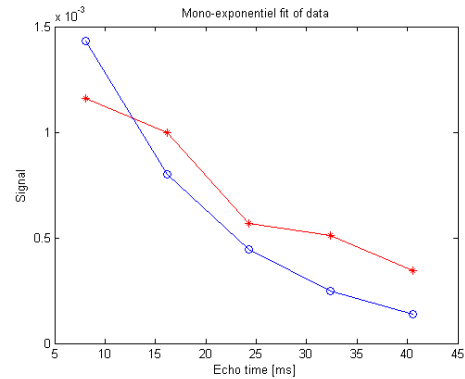


Fig.2 Mono-exponential fit example in healthy volunteer's (MID). T2 was 13.88ms. The red star curve represents the original transverse relaxation T2 curve and the blue circle curve represents the fit curve.

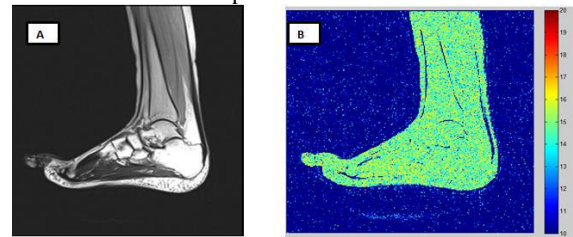


Fig.3 Example of images of a 27-year-old volunteer; A: The morphologic image acquired with MESE sequence, $TE= 8$ ms and $TR= 1500$ ms; B: The T2 map.

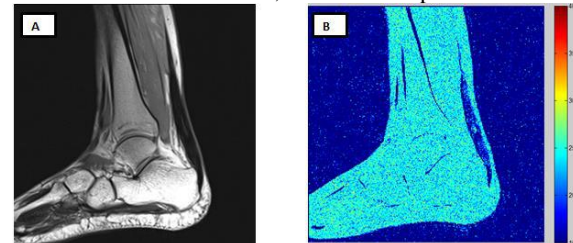


Fig.4 Example of images of a 42-year-old patient with tendinosis; A: The morphologic image acquired with MESE sequence, $TE= 8.1$ ms and $TR= 1500$ ms; B: The T2 map.

For regional evaluation of tendons, there were significant differences between the three regions. Means of T2 values as well as P values in different anatomical regions of Achilles tendon were summarized in Table II.

In volunteers there are higher values in MTJ and lower values in the MID and INS regions. In contrast, in symptomatic patients there are higher values in the MID and INS regions and lower values in MTJ.

TABLE II Summary of T2 values in volunteers and patients, and P values in different tendon regions.

Regions	Volunteers		Patients		P
	Mean (ms)	SD	Mean (ms)	SD	
INS	10.26	2.77	25.35	3.11	0.01
MID	12.87	1.03	28.07	5.74	0.01
MTJ	16.60	4.48	20.83	1.98	0.01

The plot diagram of T2 in different Achilles tendon regions for patients and volunteers is showed in figure 5.

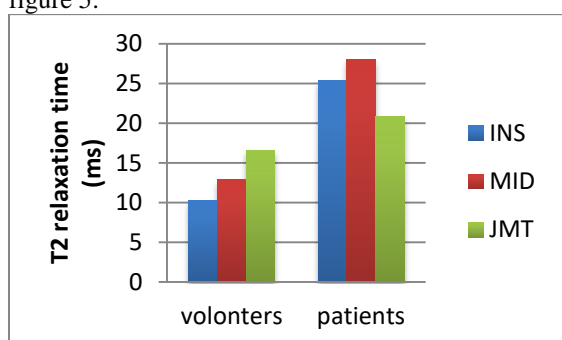


Fig.5 Plot diagram of T2 values in different Achilles tendon regions.

IV. DISCUSSION

MRI is widely used in the imaging investigation of ankle. This study evaluated Achilles tendon in vivo using quantitative T2 mapping at 3T. Our results were based on a MESE sequence which is supposed to be reliable to quantify T2 relaxation time of Achilles tendon. In addition, mono-exponential calculation of T2 using a least squares fitting provides a weighted mean value from different components of transversal relaxation and it is widely used to quantify T2 as well as T2* in tendon, cartilage and other tissue. [12, 13, 15, 16, 17]

Fukawa and al. used a multi echo spin echo sequence to determine if MR imaging T2 mapping can be used to quantify histologic tendon healing by using a rabbit Achilles transection model treated with PRP (platelet-rich plasma). They concluded that T2 mapping reflected the histologic healing process of the tendon in a rabbit Achilles tendon transection model and could be useful to quantify the healing process of the Achilles tendon. [24]

We measured T2 in healthy controls and patients with Achilles tendinosis. There was a significant difference of T2 relaxation between the healthy and tendinopathic tendons. This significant difference is in agreement with previously published results. T2 in tendon has been studied previously using various methods. [18, 24, 25, 26, 27, 28] Garry and Tishya used short echo time (TE) imaging methods with minimum echo time (TE=0.2ms) to calculate T2 in vivo Achilles tendon; the average T2 relaxation time was 1.2±0.2ms. [26]

We evaluated the regional variability of Achilles tendon based on T2 relaxation time. T2 values in Achilles tendon suggested significant variation in different anatomical region (P<0.05). Juras and Apprich used a multi echo spin echo technique with a repetition time (TR) of 1200 ms and six echo time (minimum TE=11,9ms) to investigate the feasibility of T2 mapping as potential markers for collagen, glycosaminoglycan and water content in fresh cadaver Achilles tendon; the mean T2 in INS, MID and MTJ were 21.50ms, 13.13ms and 14.36ms respectively. [27] Furthermore, regional variability of Achilles tendon were demonstrated by Juras and al. who investigated regional variations of T2* in healthy and pathologic Achilles tendon in vivo at 7T using a three dimensional ultrashort time echo (3D UTE) sequence. They observed a significant difference of T2* in several location. [17, 29]

Our findings were different to the previously published results. This difference in results can be explained by the differences in scanning parameters; we used intermediate echo time. Additionally, the differences can be influenced by several factors including the magnetic field strength of the MR units, the fitting algorithms and the unvoided experimental noises.

Magic angle effect the T2 calculation. Henkelman and al. reported that the mean T2 of in vitro dog Achilles tendon increased from 7 to 23 ms when the orientation was changed from 0° to 55°. [30] The problem is minimized in our study since we compare the same region in all subjects.

Our study has some limitations. The number of subjects is small and the population is heterogeneous. Moreover, patients and volunteers were not matched for age and gender which limits the accuracy of the results analysis.

Achilles tendon is one of the most tissues that contain short T2 components. In our methods using intermediate echo time, it was not possible to measure the shortest components of T2 values. [31] Although T2 relaxation time is a robust marker of Achilles tendon pathology, future research should investigate regional variation of Achilles tendon in vivo using exponential T2 analysis and ultrashort echo time sequence.

V. CONCLUSION

Quantative measurements of T2 relaxation time in vivo using intermediate variable echo time (TE) sequence in Achilles tendinopathy and controls has not been reported previously. This sequence can be successfully used as an alternative to quantify T2 relaxation time in tendon. Our results suggest that T2 may help to discriminate between healthy and pathologic tendons and regional variability of Achilles tendon can be quantified in vivo.

ACKNOWLEDGMENTS

The authors thank the radiology department team of the Mohamed Kassab Institute Tunis and in special radiology residents. Also, the authors thank all the

radiology technicians of the Neurology Institute in Tunis.

REFERENCES

- [1] B.R. Freedman, al., the Achilles tendon: fundamental properties and mechanisms governing healing, *Muscles, Ligaments and Tendons Journal*, 2014; 4 (2): 245-255.
- [2] M. Paavola, al, Epidemiology of tendon injuries in sports, *Clin Sports Med* 1992; 11(3):493 – 504.
- [3] S Fukashiro, PV Komi, In vivo Achilles tendon loading during jumping in humans, *Eur J Appl Physiol Occup Physiol*, 1995; 71:453-458.
- [4] TA Jarvinen, P Kannus, Achilles tendon disorders: etiology and epidemiology, *Foot Ankle Clin*, 2005; 10:255-266.
- [5] H. Weinreb, C Sheth, Tendon structure, disease, and imaging, *Muscles, Ligaments and Tendons Journal* 2014; 4 (1): 66-73.
- [6] R Hodgson, P O'Connor, Tendon and ligament imaging. *Br J Radiology*, 2012, 85(1016):1157-1172.
- [7] J DeGroot, al, Achilles tendinosis changes in biochemical composition and collagen turnover rate, *Am J Sports Med*, 2007; 35(9):1549-1556.
- [8]M. E. Schweitzer and D. Karasick, MR Imaging of Disorders of the Achilles tendon, *AJR*: 175, September 2000.
- [9] M Astrom, CF Gentz, Imaging in chronic Achilles tendinopathy: a comparison of ultrasonography, magnetic resonance imaging and surgical findings in 27 histologically verified cases, *Skeletal Radiol* 1996, 25: 615–620.
- [10]D.P. Fessell, G.M. Vanderschueren, US of the ankle: technique, anatomy and diagnosis of pathologic conditions *Radiographics*, 1998, pp. 325–340.
- [11] GE Gold, CA Chen, Recent advances in MRI of articular cartilage, *AJR Am J Roentgenol* 2009, 193:628–38.
- [12]S Trattig, S Zbyn, Biochemical MRI in Musculoskeletal Applications, *MAGNETOM Flash*, 2012.
- [13] R Kijowski, DG Blankenbaker, Evaluation of the articular cartilage of the knee joint: value of adding a T2 mapping sequence to a routine MR imaging protocol, *Radiology* 267:503–513, 2013.
- [14] MD Crema , FW Roemer , Articular cartilage in the knee: current MR imaging techniques and applications in clinical practice and research *Radio graphics* 2011;31(1):37–61.
- [15] TJ Mosher, BJ Dardzinski, Cartilage MRI T2 relaxation time mapping: Overview and applications, *Seminars in Musculoskeletal Radiology* 8, 355-368, 2004.
- [16] R J HODGSON, N MENON, Quantitative MRI measurements of the Achilles tendon in spondyloarthritis using ultrashort echo times, *The British Journal of Radiology*, 2012, e293–e299.
- [17] V Juras , S Zbyn , Regional variations of T(2)* in healthy and pathologic Achilles tendon in vivo at 7 Tesla: preliminary results. *Magn Reson Med* 2012, 68(5):1607–13.
- [18] Adam W. Anz, Erin P. Lucas, MRI T2 mapping of the asymptomatic supraspinatus tendon by age and imaging plane using clinically relevant subregions, *European Journal of Radiology* 83, 2014, 801–805.
- [19] Katharine J. Wilson, MSc, Quantifiable Imaging Biomarkers for Evaluation of the Posterior Cruciate Ligament Using 3-T Magnetic Resonance Imaging, *The Orthopaedic Journal of Sports Medicine*, 4(4), 2325967116639044.
- [20] Edmund Ganal, Charles P. Ho, Quantitative MRI characterization of arthroscopically verified supraspinatus pathology: comparison of tendon tears, tendinosis and asymptomatic supraspinatus tendons with T2 mapping, *European Society of Sports Traumatology, Knee Surgery, Arthroscopy (ESSKA)*, 2015.
- [21] Fouré A, New Imaging Methods for Non-invasive Assessment of Mechanical, Structural, and Biochemical Properties of Human Achilles tendon: A Mini Review. *Front. Physiol.* 7:324, 2016.
- [22] Timothy J. Mosher, M.D., Cartilage MRI T2 Relaxation Time Mapping: Overview and Applications, *Seminars in musculoskeletal radiology*, volume 8 number 4, 2004.
- [23]Juras, Apprich, Bi-exponential T2 analysis of healthy and diseased Achilles tendons: an in vivo preliminary magnetic resonance study and correlation with clinical score. *Eur. Radio*, 23, 2814–2822, 2013.
- [24] Fukawa, al, Quantitative Assessment of Tendon Healing by Using MR T2 Mapping in a Rabbit Achilles Tendon Transection Model Treated with Platelet-rich Plasma, *Radiology* 2015, 000:1–8.
- [25] Zheng S, Xia Y, Multi-components of T2 relaxation in ex vivo cartilage and tendon. *J. Magn. Reson.* 198:188–196, 2009.
- [26]Gold G, Wren T, In vivo short echo time imaging of Achilles tendon, *Proc Intl Soc Mag Reson Med* 9:244, 2001.
- [27] Juras V, Apprich S, Histological correlation of 7 T multi-parametric MRI performed in ex vivo Achilles tendon, *Eur J Radiol* 82:740–744, 2013.
- [28] Adam W. Anz, Erin P. Lucas, MRI T2 mapping of the asymptomatic supraspinatus tendon by age and imaging plane using clinically relevant subregions, *European Journal of Radiology* 83, 2014, 801–805.
- [29] Ulrich Grosse, Roland Syha, Diagnostic Value of T1 and T2* Relaxation Times and Off-Resonance Saturation Effects in the Evaluation of Achilles Tendinopathy by MRI at 3T, *Journal of magnetic resonance imaging*, 2014.
- [30] Henkelman RM, Stanisz GJ, Anisotropy of NMR properties of tissues, *magnetic resonance med* 1994, 32:592-601.
- [31] P. D. GATEHOUSE, G. M. BYDDER, Magnetic Resonance Imaging of Short T2 Components in Tissue, *Clinical Radiology*, 2003, 58: 1–19.